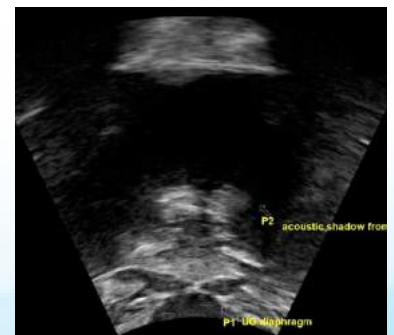
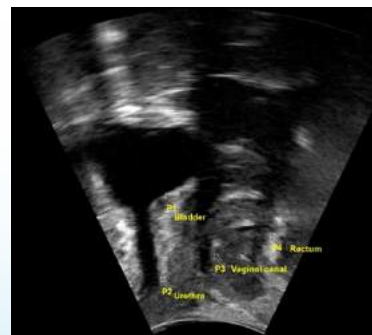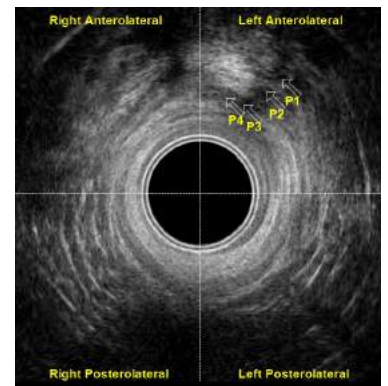
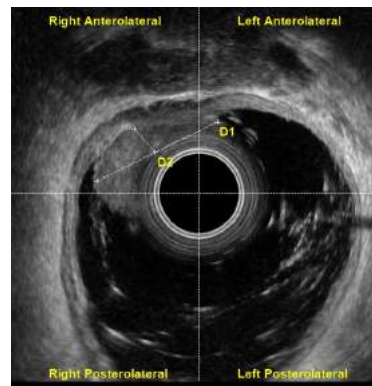


MORPHEUS®

Multicompartment Pelvic Floor Ultrasound Imaging



360° Endocavity Ultrasound Imaging

Transperineal Ultrasound Imaging

MORPHEUS® Transperineal Ultrasound Imaging

Morpheus® transperineal ultrasound imaging provides an overview of the pelvic floor anatomy and the ability to assess function with pelvic floor contractions and Valsalva maneuvers.

Sagittal View

- Prolapse
- Pelvic Floor Dyssynergia
- Mesh and Tape
- Obstruction
- Urethral Hypermobility
- Bladder Neck Descent

Transverse View

- Sphincter Anatomy
- Urethral Rotation

Abdominal View

- Bladder Wall Thickness
- Bladder Volume Measurement
- Pelvic Floor Muscle Activity and Biofeedback

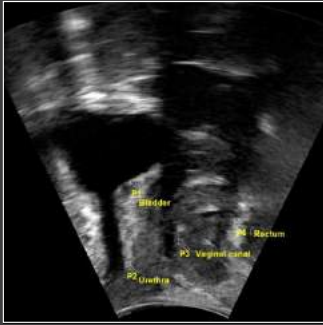

* Point of Care Cart Optional

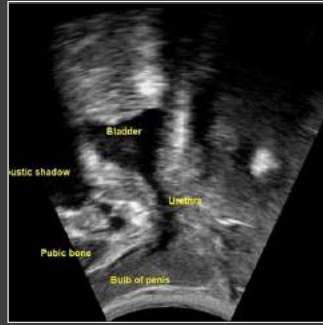Transducer Specifications:

Depth Range	Pulse Frequency	Focal Zone	Focal Point	Scan Angle	Patient Contact Sector Length	Transducer Resonant Frequency
2 - 30 cm (Selectable, 1 cm increments)	3.5 MHz, 5 MHz, 7.5 MHz (Selectable)	Programmable	Dynamic	60°	49 mm (2.5 in)	5.0 MHz

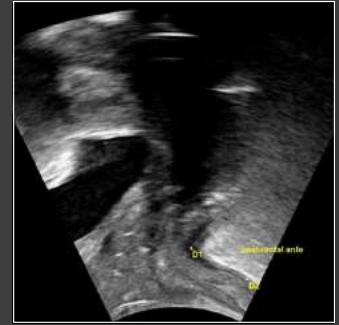Image Gallery



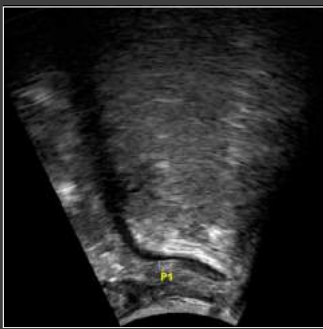Anterior Compartment with Stress Urinary Incontinence. Structures Labeled (P1, P2, P3, P4). Female.



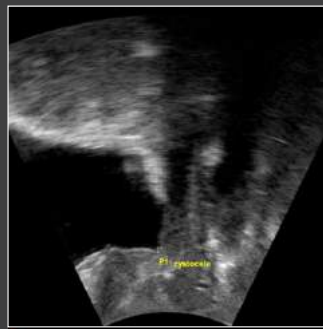Anterior Compartment Post Prostatectomy with Structures Labeled. Male.



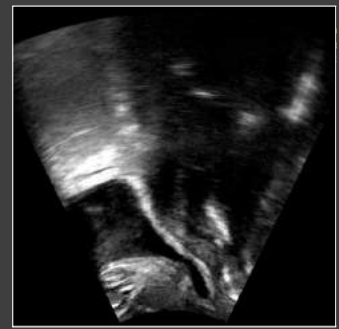Post Hysterectomy with Complaints of Chronic Pelvic Pain. Pelvic Exam Confirms Short, Tight Pelvic Floor Muscles. Posterior Compartment Ultrasound Demonstrates Acute Anal Rectal Angle During Resting State (D1, D2). Female.



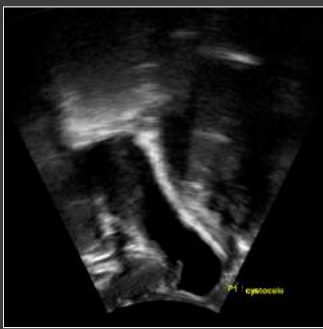Bladder Urgency, Frequency and Chronic Constipation. Posterior Compartment with Excellent Image of Anal Canal (P1). Female.



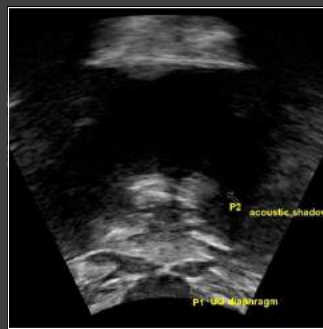Discomfort From Grade 2 Cystocele (P1). Patient in Relaxed Recumbent Position. Female.



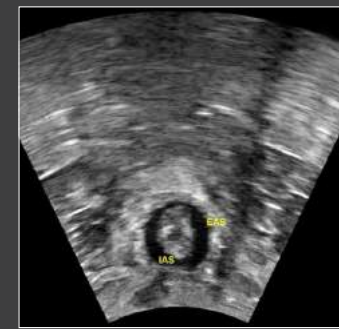Grade 3 Cystocele. Supine and Relaxed. Female.



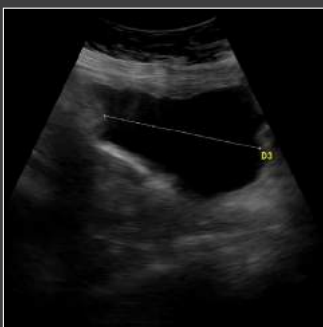Pelvic Organ Prolapse Observed During Valsalva. Female.



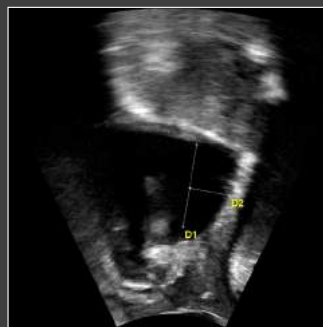Stress Urinary Incontinence and Constipation. Transperineal Image of Coronal Plane Showing Urogenital Diaphragm with Labels (P1, P2). Female.



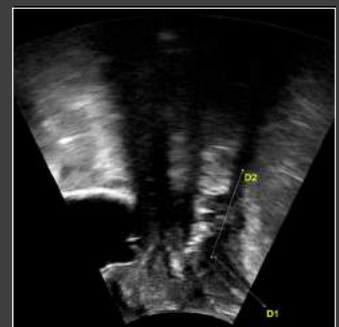Anal Incontinence and Bladder Urgency-Frequency. Cross Section of Anal Canal Taken From Perineum, Angling Toward the Table. (EAS, IAS). Sphincters Relaxed. Female.



Full Bladder Image with Volume Calculation (D3). Female.



Deflection of Posterior Edge of Bladder is Measured at 16mm. Female.



Outlet Dysfunction Constipation, Anal-Rectal Angle at Rest (D1, D2). Female.

MORPHEUS® 360° Endocavity Ultrasound Imaging

Morpheus® 360° endocavity ultrasound imaging used endoanally details normal and abnormal anorectal anatomy and is considered the gold standard in diagnostic examination for fecal incontinence. Used endovaginally, details the posterior and anterior compartments, pelvic floor contractions and provides function assessment with Valsalva maneuvers.

Visualize with Endoanal Imaging

- Fistulas and Abscesses
- Rectal Prolapse
- Obstruction
- Anal Tumors

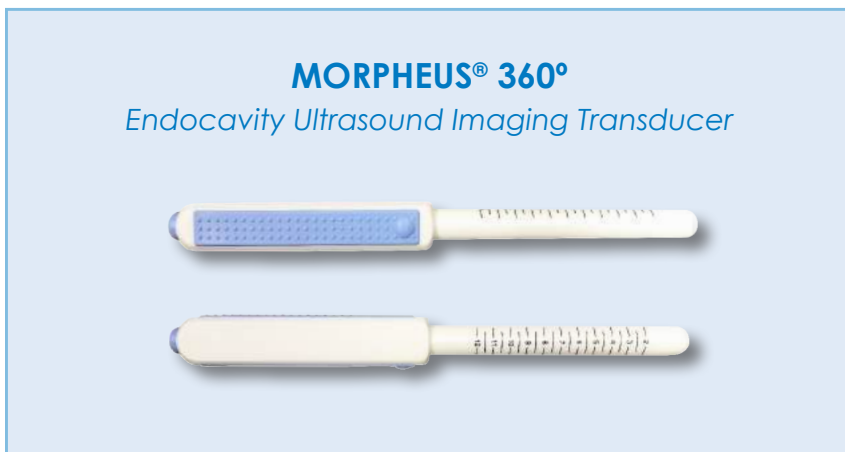
Visualize with Endovaginal Imaging

Posterior

- Anorectal Angle
- Pelvic Floor Dyssynergia
- Prolapse
- Intestinal Obstruction

Anterior

- Urethral and Muscle Length
- Bladder Symphysis Distance



* Point of Care Cart Optional

Transducer Specifications:

Depth Range	Pulse Frequency	Focal Zone	Focal Point	Scan Angle	Patient Contact Sector Length	Transducer Resonant Frequency
2, 3, and 4 cm (Selectable)	10 MHz, 12 MHz, 15 MHz (Selectable)	0.5 cm - 2 cm	1.6 cm	360°	64.1 mm (2.5 in)	12 MHz

Image Gallery

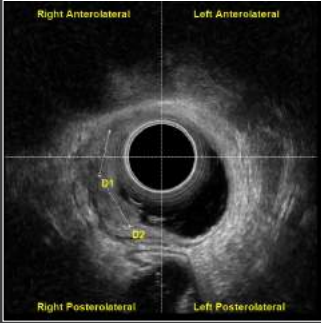
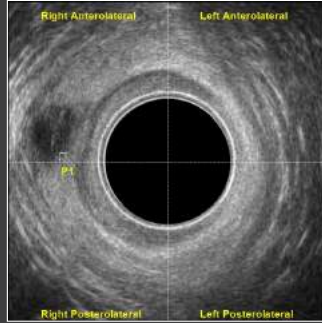
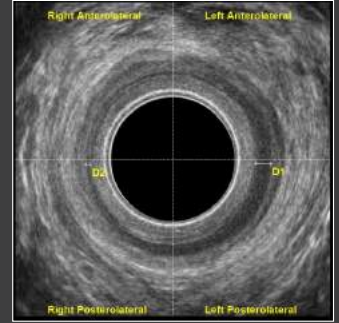


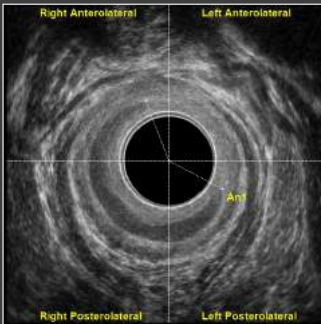
Image Corresponding to a Tumor T3 N0 (D1, D2). Female.



Low Anal Canal Collection Compatible with Perianal Abscess (P1). Male.



Marked Refinement of the Thickness of the Internal Anal Sphincter in the Right Lateral Hemian (D1,D2). Male.



Internal Anal Sphincter Injury in Left Anterolateral Quadrant at an Angle of 138° (An1). Male.

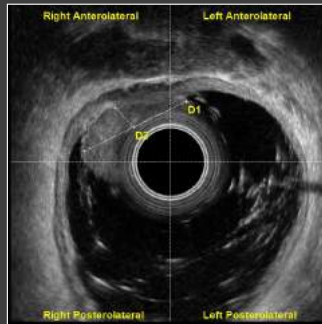
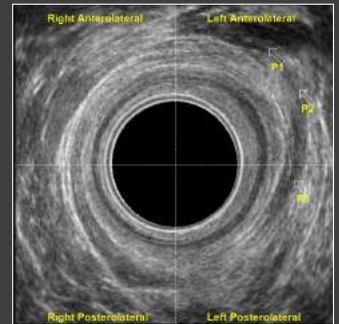
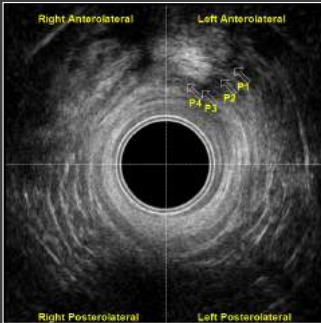


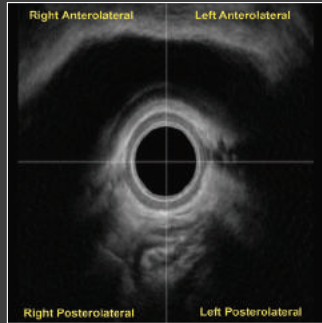
Image Corresponding to a T2 N0 (D1, D2). Male.



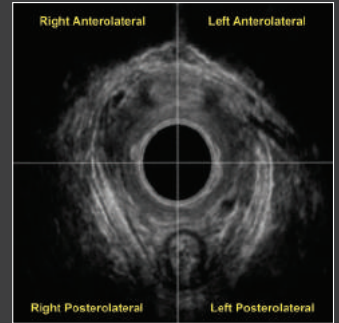
P1 Abscess in Left Anterolateral Quadrant with Secondary Course Ibsilateral (P1, P2, P3). Male.



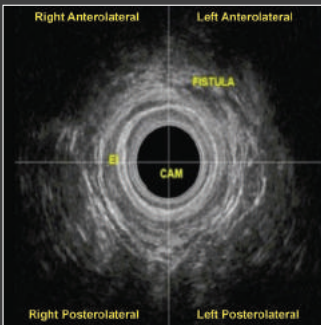
Perianal Fistula in Left Anterior Quadrant (P1, P2, P3, P4). Male.



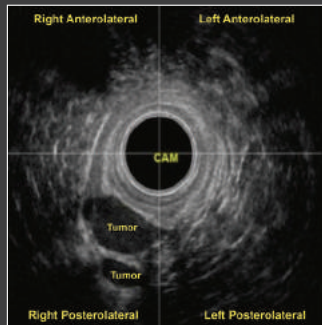
Patient with Anal Incontinence and Rectal Prolapse. The Morpheus® 360° Endocavity Ultrasound Performed Endovaginally Showed the Bladder and the Anus with a Gap in the Internal Sphincter in the Anterior Quadrant. Female.



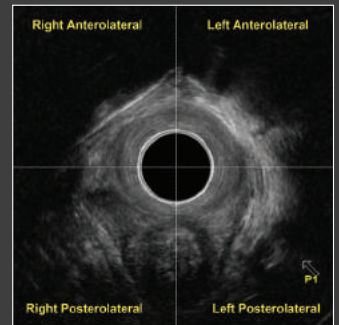
The Circular Morpheus® 360° Endocavity Transducer Can Be Utilized Endoanally or Endovaginally. The Genital Hiatus, Urethra, Pubovisceral Muscle and the Anal Sphincters Can Be Easily Seen with the Probe Placed In the Vagina. Female.



Patient with Anorectal Pain and Soiling After an Anal Abscess That Drained Spontaneously Months Ago. The Morpheus® 360° Endocavity Ultrasound Identified a Small Intersphincteric Fistula Tract. Male.



Patient with History of Rectal and Pelvic Pain During Menstrual Phase. Digital Exam Revealed a Soft Lump in the Lower Anal Canal. The Morpheus® 360° Endocavity Ultrasound Confirmed Cystic Nodules Near the Vagina and Rectum. A Diagnosis of Endometriosis was Made. Female.



Tuning of the Right Branch of the Puborectalis. Female.

Orders & Shipping

To Place an Order:

Call Customer Service toll free at **1.800.442.2325** or Fax 1.603.749.0511
Customer Service Representatives are happy to assist with processing your order or answering your questions, Monday - Friday, 9am - 5pm EST.

Payment Terms:

NET 30 Terms are available for established accounts. All major credit cards are accepted.

Shipping:

(F.O.B.) shipping point. Please allow five (5) days for delivery. Rush (air freight) orders are shipped F.O.B. shipping point.

Technical Support:

Have a question about your equipment or need technical assistance?

Call our Technical Support Team toll free at **1.800.272.8492**
Monday - Friday, 9am - 5pm EST.



The
PROMETHEUS
G R O U P[®]

LET'S GROW YOUR PRACTICE TOGETHER.

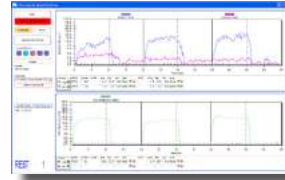
One Washington Street, Suite 3171, Dover NH, 03820
info@theprogrp.com | www.theprogrp.com | 1-800-442-2325

System Features:

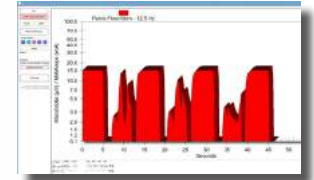
- HIPAA Compliant - Password Protection, Unique Patient Identifiers and Database Encryption
- Seamless User Interface Navigation
- Convenient One Button Start and Stop
- Comprehensive Image Quality Adjustments
- Video Capture with Frame By Frame Review
- Measure, Annotate and Save Individual Images
- Transfer Saved Images to an Analysis Attachment to Select Document Images, Provide Comments and Diagnosis in the Table of Measurements and Annotations
- Automatic Report Generation in Word and PDF Formats with Export File Path Capability

Expand Beyond Ultrasound with **MORPHEUS®**

PELVIC FLOOR REHABILITATION




Two Channel EMG with Manometry

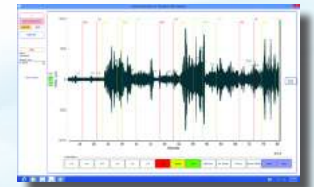


Stimulation and EMG

ANORECTAL MANOMETRY WITH PARADOXICAL EMG

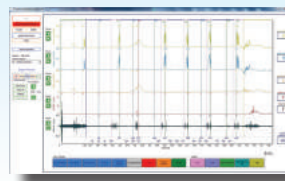


Anorectal Manometry



Paradoxical EMG

URODYNAMICS



- Voiding Cystometry
- Urethral Pressure Profiles (UPP)
- Valsalva (VLPP) and Cough (CLPP) Leak Point Pressures
- EMG
- Wireless Uroflowmetry
- Uroflowmetry with Two Channel EMG



LET'S GROW YOUR PRACTICE TOGETHER.

ISO 13485 CERTIFIED • ©The Prometheus Group®. All rights reserved.

MKT-015 Rev. A URL/UROGYN/COL

Contact us today for more information.
One Washington Street, Suite 3171, Dover NH, 03820
info@theprogrp.com | www.theprogrp.com | 1-603-749-0733